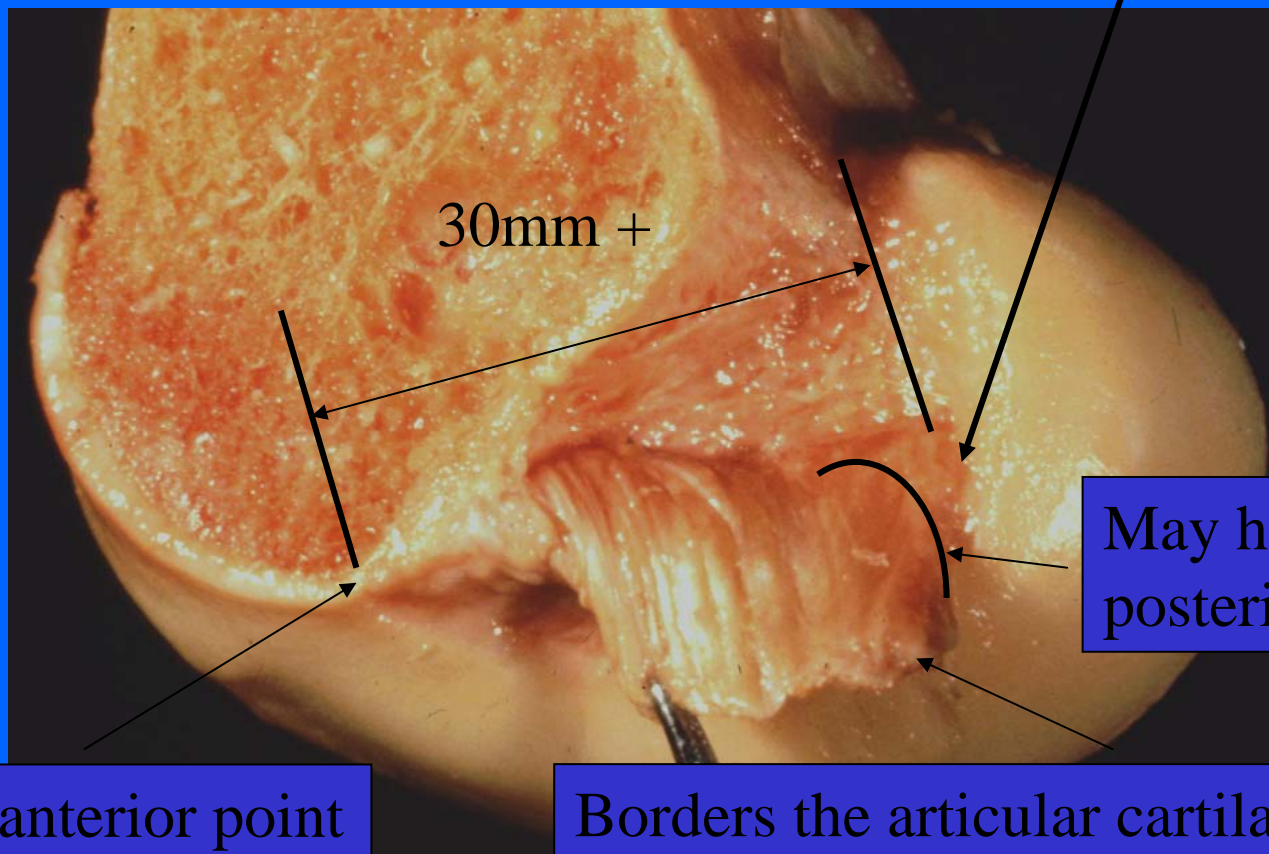
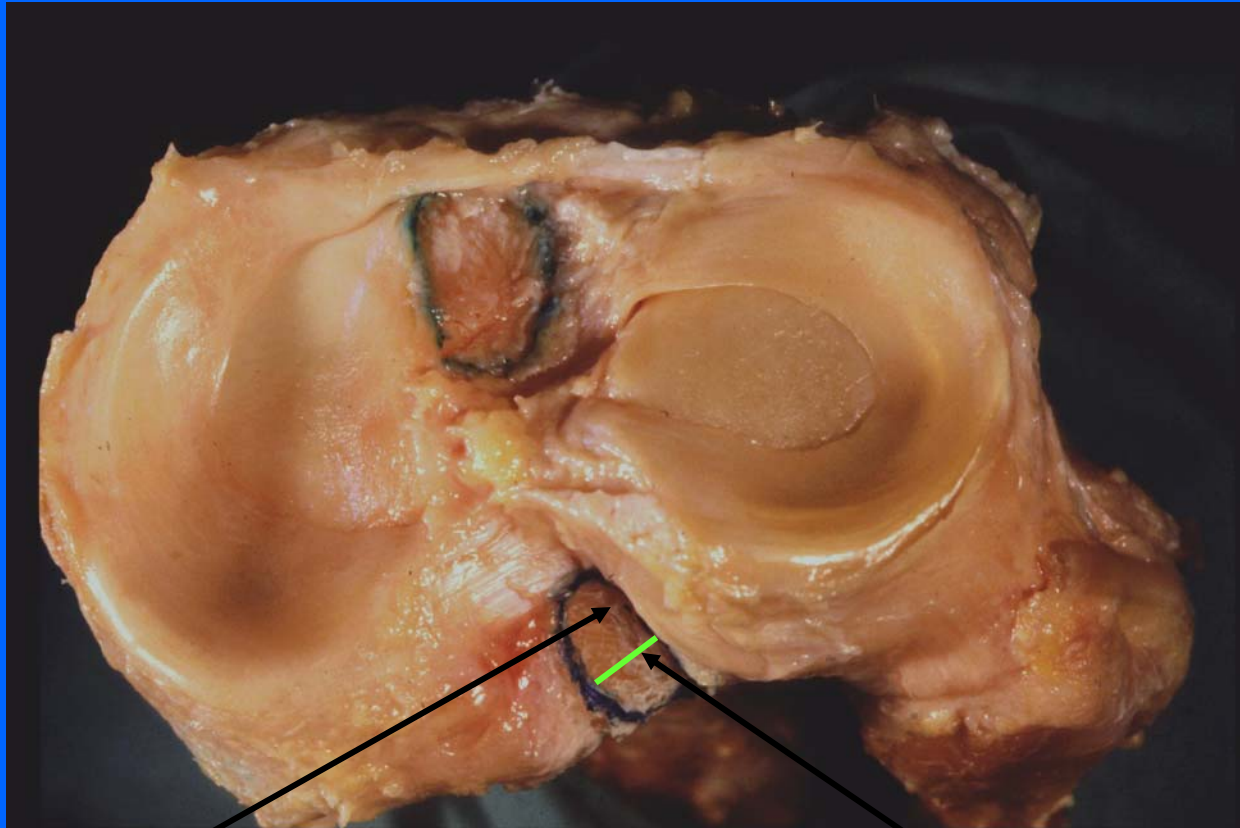


# PCL insertions

Often reaches the most posterior point inside the cartilage



# PCL insertions

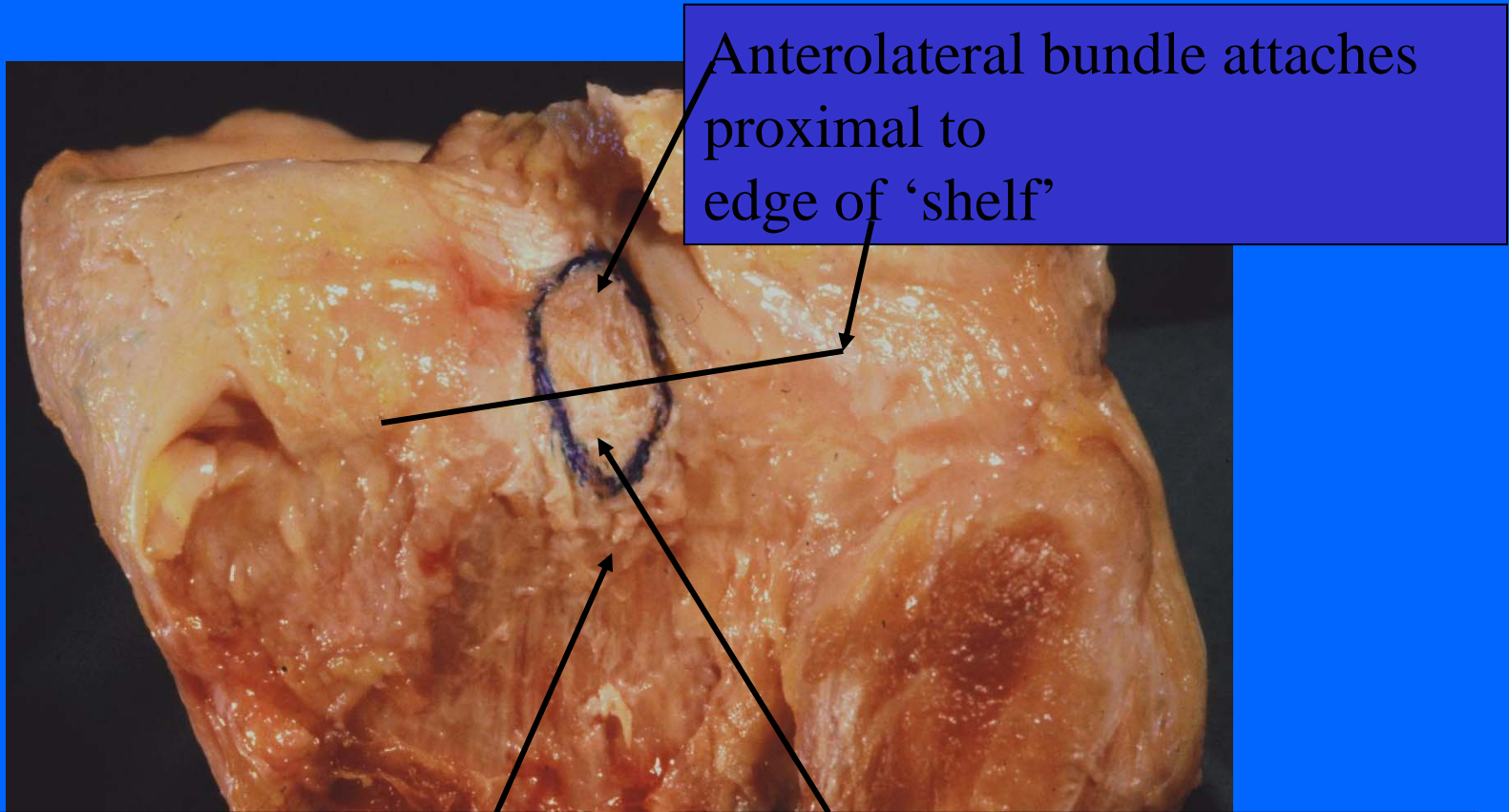


Anterolateral

bundle attachments

posteromedial

# PCL insertions

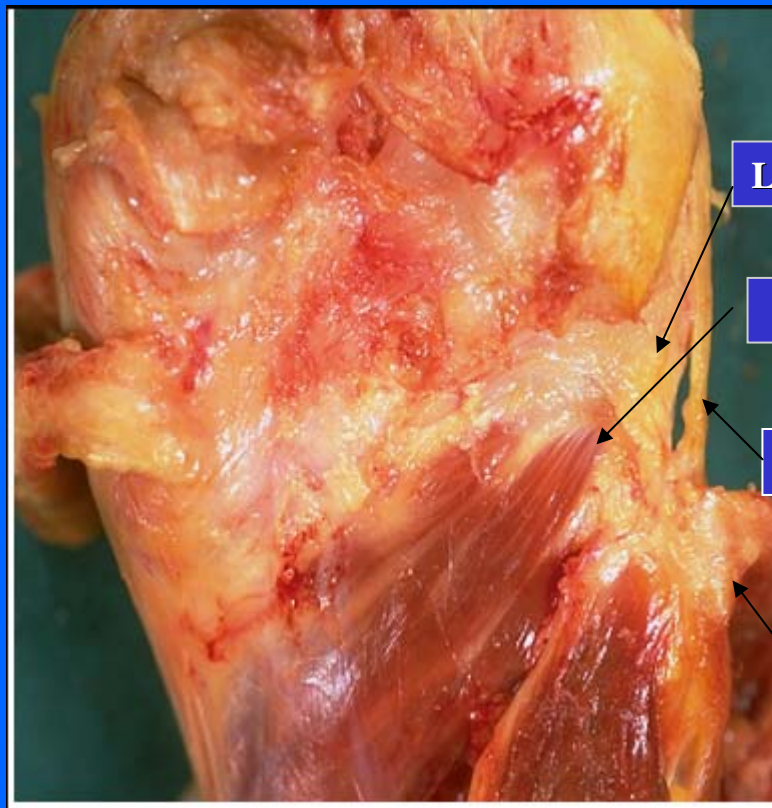


Anterolateral bundle attaches proximal to edge of 'shelf'

Most-posterior fibres dissipate periosteally

Posteromedial bundle attaches over edge of 'shelf'

# Posterolateral corner



Lig. arcuatum

Popliteus

LCL

Biceps

